

Loa loa – An Eye Worm Infestation: A Rare Case in India

Sandesh Gawade, Rohan Patil

Department of General Surgery, MIMER Medical College, Talegaon Dabhade, Pune, Maharashtra, India

ABSTRACT

Loa loa, a benign filarial nematode eye worm, is endemic in tropical rain forest areas of Africa. It is, especially, common in Cameroon, the Republic of the Congo, the Democratic Republic of the Congo, the Central African Republic, Gabon, Equatorial Guinea, and Nigeria. Travelers and migrants are more commonly found to be infected in India. In the past 100 years, very few cases have been reported in India. In our case, a 9.5 cm-long female eye worm *L. loa* was recovered from the infraorbital area of a 22-year-old young Indian lady. She presented with a swelling in the right infraorbital area over the face. A history of similar swelling in zygomatic region was noted on the same side 2 months back which disappeared of its own. After ophthalmological opinion and with routine pre-operative evaluation, she was planned for excision under local anesthesia. During procedure, a mobile structure was found suggestive of a live worm. It was further identified as a female species of *L. loa* macrofilaria on microbiological examination. The patient was advised oral diethylcarbamazine for 14 days. Post-operative follow-up for 2 years was uneventful.


Key words: Eye worm, *Loa loa*, macrofilaria

INTRODUCTION

Loa loa infestation is a type of helminthic diseases called filariasis. It is also known as “African eye worm,” due to a peculiar ocular manifestation of the disease.^[1] *L. loa* is widely distributed and highly endemic in Tropical (Equatorial) West and Central Africa.^[2] The adult worms live freely in the subcutaneous space of humans and occasionally may migrate into the subconjunctival space^[3] where

they invariably produce symptoms such as ocular pain, pruritus, tearing, and foreign body sensation.^[4] The adult worm has been found also in the anterior chamber of the eye and the subcutaneous of the eyelids.^[5] *L. loa* also known as the eye worm, causative organism of loiasis, usually benign filariasis is endemic in the rain forest belt of Western and Central Africa and Equatorial Sudan (Boussinesq and Gardon 1997).^[6] However, some reports of sporadic incidence are available from countries such as India, mostly of travelers and migrants from Africa. Maplestone first recorded a case of loiasis from an European woman in India. He described two adult female worms, one from subconjunctival tissue and another from the neck and designated as *Loa inquirenda*, as the adults differed from the classical *L. loa*.^[7]

The present report is a case of recovery of subconjunctival marofilarial female *L. loa* recovered from Pune, India.

Access this article online	
Website: www.mmj.net.in	Quick Response Code 
DOI: 10.15713/ins.mmj.33	

Address for correspondence:

Rohan Patil, Department of General Surgery, MIMER Medical College, Talegaon Dabhade, Pune, Maharashtra, India. E-mail: patilrohanashok@gmail.com

CASE REPORT

A 22-year-old lady presented with a swelling in the right infraorbital area over the face. She did not give any history of travel outside India, but she had similar swelling in zygomatic region the same side 2 months back which disappeared of its own. Despite non-significant findings after ophthalmological opinion and with routine pre-operative evaluation, she got planned for excision under local anesthesia.

On local examination, a single swelling of around 8-mm diameter was noted over infraorbital region on the right side. There were no discharge and tenderness, but minimal redness was present. No punctum seen.

Patients were considered for surgical excision under local anesthesia. A coiled, thread-like mobile structure was noted after the skin incision. Using toothed forceps, the coiled structure was removed. It suggested a long slender white living worm of the size of around 9.5 cm (Figure 1). After local irrigation with hydrogen peroxide, skin was sutured with a non-absorbable suture material. The specimen was sent for microbiological examination. Post-operative period was uneventful and sutures were removed on 6th post-operative day.

Microbiological examination report confirmed an infestation of eye worm "*L. loa*" with microscopic findings of multiple reproductive tubes suggesting it as a female worm (Figures 2 and 3). The patient was advised oral diethylcarbamazine(DEC) 100 mg, twice daily for 14 days. The patient was followed up for the next 2 years and it was uneventful.

Life Cycle

L. loa is transmitted to humans by day-biting deer flies, horse flies, or mango flies. Once inside the human body, the infective larvae develop slowly into a mature adult. During this period, it lives and moves around the facial layers of the skin. In development period, *L. loa* often makes excursions through the subdermal connective tissues. Once they reach maturity, the adults mate and produce microfilariae. The microfilariae are diurnally in synchrony with their vector, and the highest numbers are detected in blood between 10 am and 2 pm. Flies bite the human and ingest blood containing microfilariae. In the fly, they undergo two stages of growth and become infective larvae (10-12 days) which can be transmitted back to humans. Humans harboring microfilariae in the blood

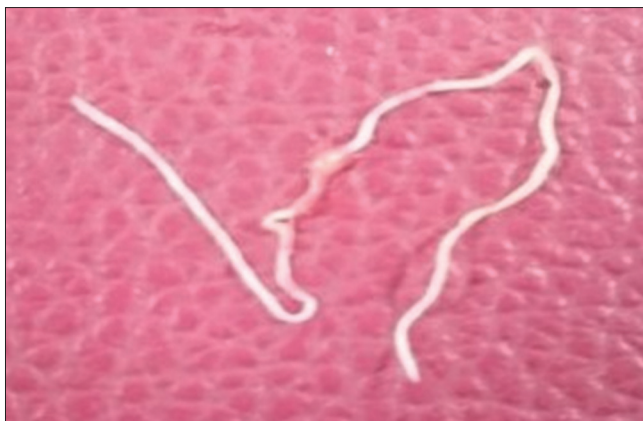

Figure 1: Gross *Loa loa* worm

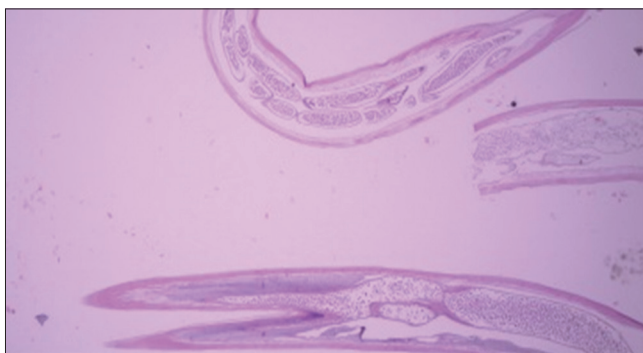


Figure 2: Micro picture of reproductive tubes of female *Loa loa*

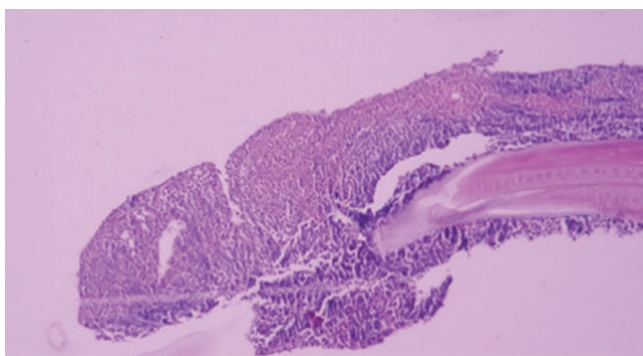


Figure 3: Head of *Loa loa* worm

are likely the most important reservoir of loiasis. Symptoms of loiasis generally do not appear until several years after the bite of an infective fly, although they have been known to appear within 4 months. Microfilariae may become apparent in peripheral blood within 5-6 months of infection and may remain in blood as long as 17 years.^[2]

Pathogenesis

Many patients infected with *L. loa* appear to be asymptomatic and the migration of the adult worm through the subcutaneous tissues often goes unnoticed, unless passing beneath the conjunctivae of the eye. When the adult worms are motionless within the subcutaneous tissues, an allergic reaction causes the so-called calabar swelling. When the worm moves on, the swelling reduces. Calabar swellings are not diagnostic of *L. loa* without other confirmations. The worms may also transit the eye beneath the conjunctivae. Subconjunctival migrations are pathognomonic for *L. loa*. These migrations cause no permanent damage to the patient but can cause localized discomfort due to swelling of the conjunctivae. Other ophthalmologic related problems due to *L. loa* infection ever published are retinal detachment and anterior chamber invasion.^[8]

DISCUSSION

In India, few cases have been reported and published. A report of loiasis was from a 20-year-old Nigerian male attending the Ophthalmology Department of S.V.R.R. Hospital, Tirupati. Two adult 15 cm female *L. loa*, one from subconjunctival tissue and another from subcutaneously below the sternal end of the left clavicle, were operated in 1988.^[9] Satyavani and Rao also reported a male *L. loa* in the anterior chamber of the left eye of a rural boy aged 10 years attending the Ophthalmic O.P.D., Government General Hospital, Kakinada.^[10] The present patient had a small calabar swelling but no microfilariaemia in peripheral blood. These findings of sporadic occurrence of *L. loa* in the people who never visited the foreign endemic areas raise doubt on the presence of vector *Chrysops* in the forest areas of Sub-Himalayan Range and source of the nematode.

L. loa needs a thorough survey of both the parasite and insect. All these reported nematodes from India are larger in size. In the present case, it is 9.5 cm. These parasites may be of simian origin which may hint at its zoonotic potentiality and raise interest as source of infection.

The treatment dose and treatment duration are controversial. The Merck Manual notes 3 mg/kg for 14 days. Diethylcarbamazine kills both the microfilariae and adult worms. Allergic reactions are common during the early treatment stage due to an acute and massive

number of dying microfilariae. An antihistaminic and corticosteroids should be given during the first 4 days. To avoid those potential allergic reactions, treatment can be started at low dose and increased progressively. There is no immunity to loiasis and repeated infections are possible.^[11]

Personal and protective measures are advocated for temporary residents in endemic regions. The use of an effective repellent (containing dimethyl phthalate), wearing long pants, and sleeping in well-screened areas are recommended. DEC given orally once weekly (300 mg) can be effective to prevent loiasis.^[12]

CONCLUSION

L. loa worm infestation is rare in India and mostly occurs in immigrants or travelers returning from endemic areas. Loiasis should be considered in at-risk patients with an unexplained foreign body sensation to prevent significant morbidity.

REFERENCES

1. Padgett JJ, Jacobsen KH. Loiasis: African eye worm. *Trans R Soc Trop Med Hyg* 2008;102:983-9.
2. Hawking F. The distribution of human filariasis throughout the world. Part III. Africa. *Trop Dis Bull* 1977;74:649-79.
3. Jain R, Chen JY, Butcher AR, Casson R, Selva D. Subconjunctival *Loa loa* worm. *Int J Infect Dis* 2008;12:e133-5.
4. Eballe AO, Epée E, Koki G, Owono D, Mvogo CE, Bella AL, *et al.* Intraocular live male filarial *Loa loa* worm. *Clin Ophthalmol* 2008;2:965-7.
5. Barua P, Barua N, Hazarika NK, Das S. *Loa loa* in the anterior chamber of the eye: A case report. *Indian J Med Microbiol* 2005;23:59-60.
6. Fain A. Current problems of loiasis. *Bull World Health Organ* 1978;56:155-67.
7. Maplestone PA. A new filarial worm from human being. *Indian Med Gaz* 1983;73:8-10.
8. Cârstocea B, Pintilie E. Ocular filariasis with retinal detachment. *Oftalmologia* 1993;37:210-4.
9. Lakshmi N, Kumar GA. Loiasis (a case report). *Indian J Ophthalmol* 1988;36:98-9.
10. Satyavani M, Rao KN. Live male adult *Loa loa* in the anterior chamber of the eye a case report. *Indian J Pathol Microbiol* 1993;36:154-7.
11. Nutman TB, Miller KD, Mulligan M, Ottesen EA. *Loa loa* infection in temporary residents of endemic regions: Recognition of a hyperresponsive syndrome

with characteristic clinical manifestations. J Infect Dis 1986;154:10-8.

12. Ottesen EA. Efficacy of diethylcarbamazine in eradicating infection with lymphatic-dwelling filariae in humans. Rev Infect Dis 1985;7:341-56.

How to cite: Gawade S, Patil R. *Loa loa* – An Eye Worm Infestation: A Rare Case in India. MIMER Med J 2018;2(2):44-47.

Source of Support: Nil. **Conflict of Interest:** None declared.

This work is licensed under a Creative Commons Attribution 4.0 International License. The images or other third party material in this article are included in the article's Creative Commons license, unless indicated otherwise in the credit line; if the material is not included under the Creative Commons license, users will need to obtain permission from the license holder to reproduce the material. To view a copy of this license, visit <http://creativecommons.org/licenses/by/4.0/> © Gawade S, Patil R. 2018