

A rare case of fungating phyllodes tumor of the breast

Shantata Jayant Kudchadkar, Shireesha Umakant Chodankar, Dilip Amonkar

Department of General Surgery, Goa Medical College, Bambolim, Goa, India

ABSTRACT

Phyllodes tumor of the breast is an uncommonly encountered disease. They are rare fibroepithelial tumors that constitute <1% of all known breast neoplasms. These tumors were first characterized by Johannes Muller in 1838, and he coined the term cystosarcoma phyllodes to describe them, based on the “leaf-like” projections into cystic spaces and sarcomatous stroma. However, this is a misleading term as 70% of these tumors are benign in nature and only rarely demonstrate cystic features. These tumors may appear as benign fibroadenoma-like lesions, locally recurrent aggressive tumors, or widely metastatic malignant forms. When these advanced tumors ulcerate, they reduce the quality of life dramatically because of associated pain, infection, malodor, profuse discharge, and bleeding. The standard of care for the treatment of phyllodes tumor entails complete surgical excision with a margin of >1 cm. They most commonly metastasize through hematogenous spread; thus, there is no role for axillary lymph node dissection for the staging of these tumors. Local recurrent rates have been shown to decrease with the administration of adjuvant radiation therapy for borderline or malignant tumors following wide local excision. The tumor presenting as a fungating breast mass or “ruptured” breast is an even more rare presentation of an unusual disease. We report a case with an atypical presentation of a 60-year-old female with a huge exophytic fungating mass of the left breast infected with maggots. Cytology was suggestive of malignancy, so left mastectomy was performed. The final pathology report was consistent with phyllodes tumor. Our aim is to highlight the features of this rare breast cancer and the challenges in obtaining a definitive diagnosis.

Key words: Malignancy, phyllodes tumor, rupture breast, simple mastectomy


INTRODUCTION

Phyllodes tumours of the breast, previously sometimes known as Serocystic Disease of Brodie or Cystosarcoma phyllodes are real giant fibroadenomas, usually seen in women of over 40 years of age but can appear in younger women. Main complaint is huge swelling with an unevenly bosselated surface, though occasionally

patients may complain of serous discharge through the nipple. The subcutaneous veins become prominent. Occasionally, ulceration of overlying skin occurs because of pressure necrosis. Despite their size, they remain mobile on the chest wall. The axillary lymph nodes become rarely enlarged only secondary to infections.

Histologically, there is a wide variation in their appearance, with some of low malignant potential resembling a fibroadenoma & others having a high mitotic index which has to be differentiated. The latter are rarely cystic & only very rarely develop features of sarcomatous tumor.

Conditions to be considered in the differential diagnosis of phyllodes tumour include breast carcinoma, breast abscess, fat necrosis, angiosarcoma, radial scar & sclerosing adenosis. No specific hematologic tumor markers or other blood tests can be used to diagnose phyllodes tumors, though expression of biologic

Access this article online	
Website: www.mimer.com	Quick Response Code 
DOI: 10.15713/ins.mmj.28	

Address for correspondence:

Shireesha Umakant Chodankar, Senior Resident, Department of General Surgery, Goa Medical College, Bambolim, Goa, India. E-mail: shantatak@gmail.com

markers can discriminate between different grades of tumor.^[1,2] The immunohistochemical expression of CD10 can predict the occurrence of distant metastasis.^[3] Investigation of a malignant phyllodes tumor with whole genomic and proteomic analysis revealed chromosome mutations, amplifications, and deletions.^[4] Further exploration of the biology of phyllodes tumor may lead to the development of targeted treatments.^[5-9]

Currently, the diagnosis is usually based on clinical suspicion & histological analysis. The treatment of choice is wide local excision with negative margins for benign & borderline phyllodes tumour while massive tumours, recurrent tumours & those of malignant type will require mastectomy. Continued follow-up care is necessary. An initial visit 1-2 weeks after surgery to detect any initial complications should be followed by periodic visits as determined by the patient's surgeon.

CASE REPORT

A 60-year-old female, native of Sawantwadi, presented to casualty with fungating mass of the left breast for many years with foul smelling discharge and infected with maggots for 15 days. On local examination, a large proliferative mass measuring 15 cm × 18 cm in size was present in upper outer quadrant of left breast with ulcer measuring 8 cm × 6 cm with the destruction of nipple-areola complex and infected with maggots and slough [Figure 1]. Other breast and bilateral axilla examination was normal. Systemic examination was normal. The patient was anemic with Hb of 8 g %.

Desloughing and removal of maggots were done initially, and the patient was started on IV antibiotics. Subsequently, she was further evaluated and cytological examination was suggestive of malignancy. Considering a diagnosis of locally advanced breast cancer, a full metastatic workup including chest X-ray and abdominal ultrasound was done which was normal. Due to patient's poor social condition (uncared for and abandoned), she consented only for a simple mastectomy which was performed within a week. Postoperatively, wound was healthy, and the patient was discharged on antibiotics.

On follow-up, patient's recovery was uneventful and wound was healthy. Histopathology report revealed borderline phyllodes tumor [Figures 2a and b]. Hence, considering patient's age and tissue report, she was advised regular follow-up and observation. Subsequent follow-ups for 1 year were uneventful.

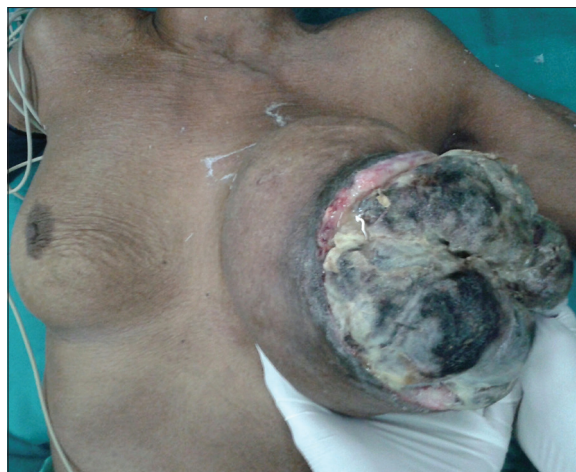

Figure 1: Gross appearance of fungating phyllodes tumour of left breast

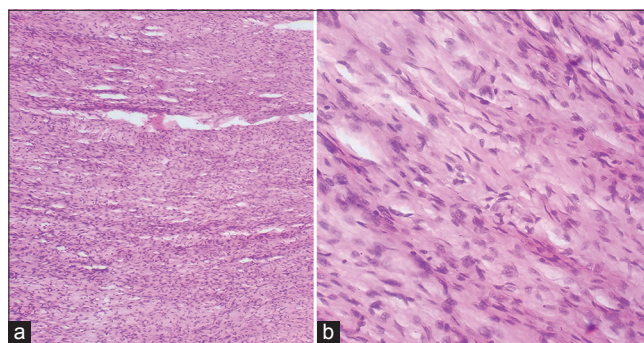


Figure 2: (a and b) Cytopathophysiology slides showing stromal cells of low mitotic activity (Hematoxylin & Eosin Stain ×100 & ×400 magnification)

DISCUSSION

The diagnosis largely relies on clinical suspicion and is often not determined until the pathology of the surgically excised lesion is reviewed. Mammography and ultrasonography do not yield conclusive signs, and histology is the mainstay in establishing the diagnosis.

Treatment is mainly by surgical excision with adequate margins. Wide excision with negative margins is the treatment of choice for benign and borderline phyllodes tumor, while simple mastectomy may be reserved for the malignant variety.^[10] In certain situations, mastectomy and breast reconstruction may be the only reasonable option for large benign phyllodes tumors which has completely replaced normal breast tissue.^[11] Overall recurrence rate following wide excision varies from 3.4% to 13.2%.^[12]

This tends to occur locally, more common with benign phyllodes tumor and is directly related to the grade of the phyllodes tumor and resection margins.

There is no evidence of benefit with adjuvant therapies but can be considered on individual case-by-case basis. Adjuvant radiotherapy may be considered for high-risk phyllodes tumor, including those >5 cm, with stromal overgrowth, with >10 mitoses per high-power field, or with positive margins.^[13] As there is a risk of local and distant metastases, the follow-up of the patients is mandatory.^[10]

CONCLUSION

Phyllodes tumors are extremely uncommon neoplasms that are usually benign. Patients typically present with a well-circumscribed, painless, firm, and mobile mass or nodule characterized by rapid growth in a short period of time. Even though benign, they can mimic a malignant breast tumor, especially if they ulcerate the overlying skin. They can also fungate causing a diagnostic challenge as highlighted in this report. Post-op follow up of our patient over 1 year by CXR and abdominal and pelvic ultrasound did not reveal any evidence of metastasis. Patient was discharged on hematinics along with antibiotics and her anemia was corrected with Hb of 12.2 gm% at the end of 1 year.

Also our patient was abandoned and uncared for and brought to the hospital by her neighbours for cleaning and dressing. After initial debridement and cytopathology report, patient only consented for simple mastectomy procedure and was not willing for any reconstruction so this option was not considered in her case in view of her poor socioeconomic condition and no family support.

REFERENCES

- Jung YY, Lee YK, Koo JS. Expression of lipid metabolism-related proteins in breast phyllodes tumors. *Neoplasma* 2016;63:254-62.
- Bellezza G, Prospero E, Del Sordo R, Colella R, Rulli A, Sidoni A, et al. IMP3 is strongly expressed in malignant phyllodes tumors of the breast: An immunohistochemical study. *Int J Surg Pathol* 2016;24:37-42.
- Al-Masri M, Darwazeh G, Sawalhi S, Mughrabi A, Sughayer M, Al-Shatti M, et al. Phyllodes tumor of the breast: Role of CD10 in predicting metastasis. *Ann Surg Oncol* 2012;19:1181-4.
- Jardim DL, Conley A, Subbiah V. Comprehensive characterization of malignant phyllodes tumor by whole genomic and proteomic analysis: Biological implications for targeted therapy opportunities. *Orphanet J Rare Dis* 2013;8:112.
- Shin YD, Lee SK, Kim KS, Park MJ, Kim JH, Yim HS, et al. Collision tumor with inflammatory breast carcinoma and malignant phyllodes tumor: A case report and literature review. *World J Surg Oncol* 2014;12:5.
- Jardim DL, Conley A, Subbiah V. Comprehensive characterization of malignant phyllodes tumor by whole genomic and proteomic analysis: Biological implications for targeted therapy opportunities. *Orphanet J Rare Dis* 2013;8:112.
- Liang MI, Ramaswamy B, Patterson CC, McKelvey MT, Gordillo G, Nuovo GJ, et al. Giant breast tumors: Surgical management of phyllodes tumors, potential for reconstructive surgery and a review of literature. *World J Surg Oncol* 2008;6:117.
- Ang MK, Ooi AS, Thike AA, Tan P, Zhang Z, Dykema K, et al. Molecular classification of breast phyllodes tumors: Validation of the histologic grading scheme and insights into malignant progression. *Breast Cancer Res Treat* 2011;129:319-29.
- Reinfuss M, Mitsuś J, Duda K, Stelmach A, Ryś J, Smolak K, et al. The treatment and prognosis of patients with phyllodes tumor of the breast: An analysis of 170 cases. *Cancer* 1996;77:910-6.
- Guillot E, Couturaud B, Reyat F, Curnier A, Ravinet J, Laé M, et al. Management of phyllodes breast tumors. *Breast J* 2011;17:129-37.
- Arcuri MF, Del Rio P, Martella EM, Bezer L, Sianesi M. Giant malignant phylloides tumor: Case report. *G Chir* 2007;28:251-2.
- Kim S, Kim JY, Kim DH, Jung WH, Koo JS. Analysis of phyllodes tumor recurrence according to the histologic grade. *Breast Cancer Res Treat* 2013;141:353-63.
- Asoglu O, Ugurlu MM, Blanchard K, Grant CS, Reynolds C, Cha SS, et al. Risk factors for recurrence and death after primary surgical treatment of malignant phyllodes tumors. *Ann Surg Oncol* 2004;11:1011-7.